

## CASE REPORT

## AVASCULAR NECROSIS OF THE FEMORAL HEAD IN PATIENT WITH LYME DISEASE AND DEVIC'S OPTIC NEURITIS

Vilijam Velkovski<sup>1</sup>, Ilir Shabani<sup>1</sup>, Viktor Kamnar<sup>1</sup>, Antonio Gavrilovski<sup>1</sup>, Teodora Todorova<sup>1</sup>, Milena Bogojevska-Doksevska<sup>1</sup>, Danica Popovska<sup>1</sup>, Erieta Nikolikj-Dimitrova<sup>2</sup>

<sup>1</sup> University Clinic for Traumatology, Orthopedics, Anesthesiology, Reanimation and Intensive Care; Ss Cyril and Methodius University in Skopje, Faculty of Medicine, Republic of North Macedonia

<sup>2</sup> University Clinic for Physical Medicine and Rehabilitation; Faculty of Medicine, Ss. Cyril and Methodius University in Skopje, Republic of North Macedonia

## Abstract

Avascular necrosis of the femoral head is a condition that leads to the collapse of the femoral head, which eventually ends in osteonecrosis of the hip head and the need for a total hip replacement. It affects patients of both sexes between 20-55 years of age. The pathogenetic cause is a progressive reduction of blood circulation which leads to destruction of the femoral head. Most often the causes are corticosteroid therapy, alcoholism, smoking, trauma, etc. Decompression of the femoral head accompanied by application of mesenchymal stem cells to the necrotic zone is a promising regenerative method of treatment. We present a case of a 20-year-old patient who was diagnosed with avascular necrosis of the femoral head of the left hip, due to a high dosage of corticosteroid therapy, with Lyme disease and Devic's optic neuritis. Corticosteroid-induced avascular necrosis of the femoral head most commonly affects the femoral head, but other skeletal parts are not excluded. Majority of patients complain of pain with an insidious onset, which exacerbates with physical activity, and tends to worsen with time. Early diagnosis and treatment are crucial. Despite some controversy regarding the treatment of avascular necrosis of the femoral head with stem cells, the general outcomes of using stem cells appear to be positive in terms of efficacy and safety.

**Citation:** Velkovski V, Shabani I, Kamnar V, Gavrilovski A, Todorova T, Bogojevska-Doksevska M, Popovska D, Nikolikj-Dimitrova E. Avascular necrosis of the femoral head in patient with Lyme disease and Devic's optic neuritis. Arch Pub Health 2023; 15(1). doi.org/10.3889/aph.2023.6078

OnlineFirst

**Key words:** avascular necrosis, femoral head, stem cells

**\*Correspondence:** Vilijam Velkovski, University Clinic for Traumatology, Orthopedics, Anesthesiology, Reanimation and Intensive Care, Skopje, Republic of North Macedonia;

E-mail: vilijamvelkovski@gmail.com

**Received:** 10-Jan-2023; **Revised:** 25-Feb-2023; **Accepted:** 28-Feb-2023; **Published:** 30-Mar-2023

**Copyright:** © 2023. Vilijam Velkovski, Ilir Shabani, Viktor Kamnar, Antonio Gavrilovski, Teodora Todorova, Milena Bogojevska-Doksevska, Danica Popovska, Erieta Nikolikj-Dimitrova. This is an open-access article distributed under the terms of the Creative Commons Attribution License, which permits unrestricted use, distribution, and reproduction in any medium, provided the original author(s) and source are credited.

**Competing Interests:** The author have declared that no competing interests

## ПРИКАЗ НА СЛУЧАЈ

## АВАСКУЛАРНА НЕКРОЗА НА ГЛАВАТА НА БУТНАТА КОСКА КАЈ ПАЦИЕНТ СО ЛАЈМСКА БОЛЕСТ И ДЕВИКОВ ОПТИЧКИ НЕВРИТИС

Вилијам Велковски<sup>1</sup>, Илир Шабани<sup>1</sup>, Виктор Камнар<sup>1</sup>, Антонио Гавриловски<sup>1</sup>, Теодора Тодорова<sup>1</sup>, Милена Богојевска-Доксевска<sup>1</sup>, Даница Поповска<sup>1</sup>, Ериета Николкиќ-Димитрова<sup>2</sup>

<sup>1</sup> Универзитетска клиника за трауматологија, ортопедија, анестезиологија, реанимација и интензивно лекување; Универзитет „Св. Кирил и Методиј“ во Скопје, Медицински факултет, Република Северна Македонија

<sup>2</sup> Универзитетска клиника за физикална медицина и рехабилитација, Медицински факултет, Универзитет „Св. Кирил и Методиј“ во Скопје, Република Северна Македонија

## Извадок

**Цитирање:** Велковски В, Шабани И, Камнар В, Гавриловски А, Тодорова Т, Богојевска-Доксевска М, Поповска Д, Николкиќ-Димитрова Е. Аvascular necrosis of the femoral head in patient with Lyme disease and Devic's optic neuritis. Arch J Здравје 2023;15(1) doi.org/10.3889/aph.2023.6078

OnlineFirst

**Клучни зборови:** аваскуларна некроза, глава на бутна коска, матични клетки

**\*Кореспонденција:** Вилијам Велковски, Универзитетска клиника за трауматологија, ортопедија, анестезиологија, реанимација и интензивно лекување, Скопје, Република Северна Македонија E-mail: vilijamvelkovski@gmail.com

**Примено:** 10-јан-2023; **Ревидирано:** 25-фев-2023; **Прифатено:** 28-фев-2023; **Објавено:** 30-мар-2023

**Печатарски права:** ©2023 Вилијам Велковски, Илир Шабани, Виктор Камнар, Антонио Гавриловски, Теодора Тодорова, Милена Богојевска-Доксевска, Даница Поповска, Ериета Николкиќ-Димитрова. Оваа статија е со отворен пристап дистрибуирана под условите на нелицензирана лиценца, која овозможува неограничена употреба, дистрибуција и репродукција на било кој медиум, доколку се цитираат оригиналните автор(и) и изворот.

**Конкурентски интереси:** Авторот изјавува дека нема конкурентски интереси.

Аvascular necrosis of the femoral head is a condition that leads to the collapse of the femoral head, which eventually ends in osteonecrosis of the hip head and the need for a total hip replacement. It affects patients of both sexes between 20-55 years of age. The pathogenetic cause is a progressive reduction of blood circulation which leads to destruction of the femoral head. Most often the causes are corticosteroid therapy, alcoholism, smoking, trauma, etc. Decompression of the femoral head accompanied by application of mesenchymal stem cells to the necrotic zone is a promising regenerative method of treatment. We present a case of a 20-year-old patient who was diagnosed with avascular necrosis of the femoral head of the left hip, due to a high dosage of corticosteroid therapy, with Lyme disease and Devic's optic neuritis. Corticosteroid-induced avascular necrosis of the femoral head most commonly affects the femoral head, but other skeletal parts are not excluded. Majority of patients complain of pain with an insidious onset, which exacerbates with physical activity, and tends to worsen with time. Early diagnosis and treatment are crucial. Despite some controversy regarding the treatment of avascular necrosis of the femoral head with stem cells, the general outcomes of using stem cells appear to be positive in terms of efficacy and safety.

## Introduction

Avascular necrosis of the femoral head (AVN) is a condition that leads to collapse of the femoral head, which eventually ends in osteonecrosis of the hip head and the need for a total hip prosthesis. This is a condition that affects patients of both sexes between 20-60 years of age. The pathogenetic cause is a progressive reduction of blood circulation which leads to destruction of the femoral head.<sup>1-4</sup> The etiological causes are multifactorial.<sup>5</sup> Most often the causes are corticosteroid therapy, alcoholism, smoking, trauma, etc. The symptomatology and radiological findings depend on the degree of damage to the femoral head, classified according to the Ficat classification.<sup>6</sup> The main symptoms are pain and limited internal rotation of the hip. The exact assessment of the degree of damage is determined by magnetic resonance imaging.

There are several types of surgical methods in the treatment of AVN, from decompression of the hip head, osteotomy, bone graft and finally total hip replacement surgery. Decompression of the femoral head accompanied by application of mesenchymal stem cells to the necrotic zone is a promising regenerative method of treatment.<sup>7</sup> Stem cells are obtained by harvesting bone marrow aspirate from the iliac bone. Satisfactory clinical and radiographic results have been reported in patients classified after Ficat I and II classification in 75% of cases and more than 40% in patients classified as Ficat stage III. The mechanism re-

fers to the increased proliferation of cells in the process of construction and remodeling of the decompressed necrotic zone. Biological efficiency is determined by the activity of cytokines and growth factors (beta growth factor, interleukin<sup>8</sup>, stromal cellular alpha factor and vascular endothelial growth factor), which act as mediators in the regeneration of the bone matrix and allow its further remodeling. All this results in slowing down the process of chondral degeneration, subchondral sclerosis and definite arthrosis of the hip joint which is treated exclusively with alloarthroplasty, a total hip replacement.<sup>8</sup>

The procedure is a simple, bloodless, short-term method with unknown complications. Patients can tolerate stress and return to daily activities and functional life early.<sup>9</sup>

## Case report

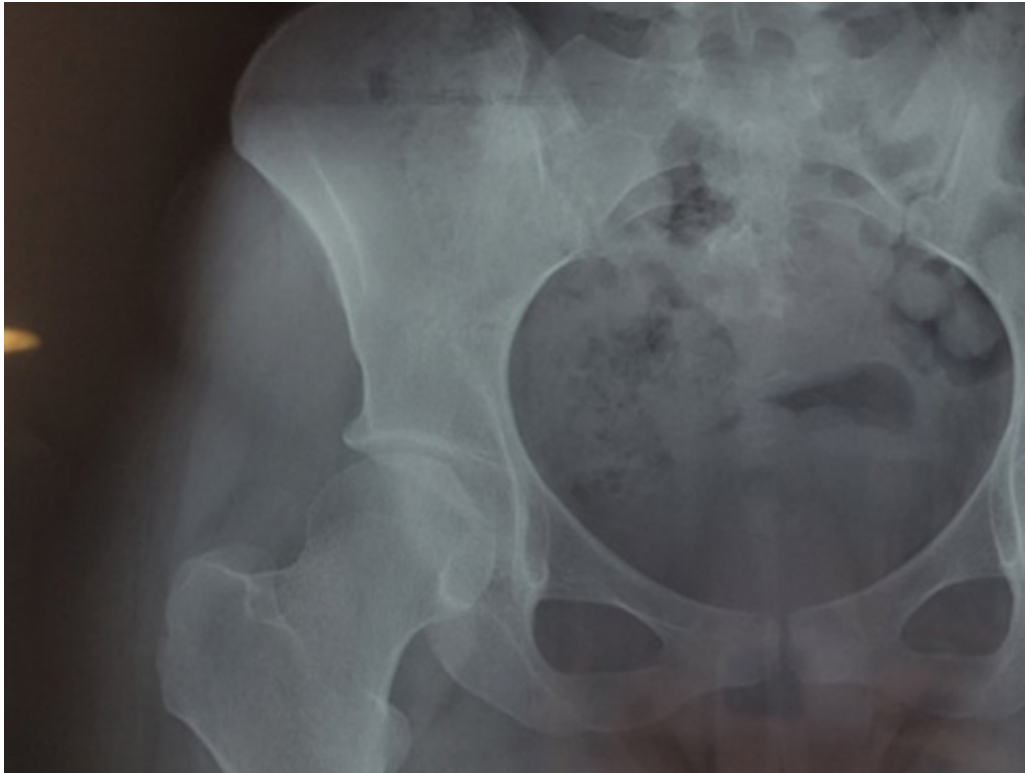
We present a case of a 20-year-old female patient treated at the University Clinic for Neurology due to an acute demyelinating process, transverse myelitis. Positive Borrelia IgM titer and positive Western-Blot test were obtained during hospitalization. The patient was treated with a high dosage of corticosteroids. After the hospital treatment, rehabilitation was performed for 4 weeks, followed by improvement of sensitivity, stability when walking, control of urination. She was referred to the University Clinic for Infectious Diseases where after a diagnostic lumbar puncture she was hospitalized for further examination and treatment.

The patient presented to the University Clinic for Orthopedic diseases for examination due to pain in the left inguinal region, the left hip, which radiated along the left leg, for a period longer than 6 months. Limited and painful hip flexion as well as external rotation were followed up for clinical examination. According to the VAS scale, the patient rated the degree of pain with a score of 8, and the value for the Harris Hip Score was 44. Pelvic X-rays and magnetic resonance imaging were performed in support of avascular necrosis of the femoral head of the left hip, according to the Ficat classification stage III. After the clinical and paraclinical examinations, an indication was set for surgical treatment. Decompression and application of mesenchymal stem cells, which were taken from the bone marrow of the iliac bone, was performed. They were processed by centrifugation and separation using the Artrex Angel system. The patient was introduced to spinal anesthesia and placed on an extension chair. 180 ml of bone marrow were aspirated using a 6 cm long trocar needle 1.5 mm in diameter placed in the anterolateral part of the iliac crest. It was transferred to a plastic container with anticoagulant and further preparation in a centrifuge followed to separate the stem cells from the blood elements. The prepared device was implanted through a trocar directly into the decompressed necrotic segment as well as intraarticularly in the hip joint. Quality cytometry was performed to control the quality, the total number of nuclear cells and their viability. The patient was verticalized

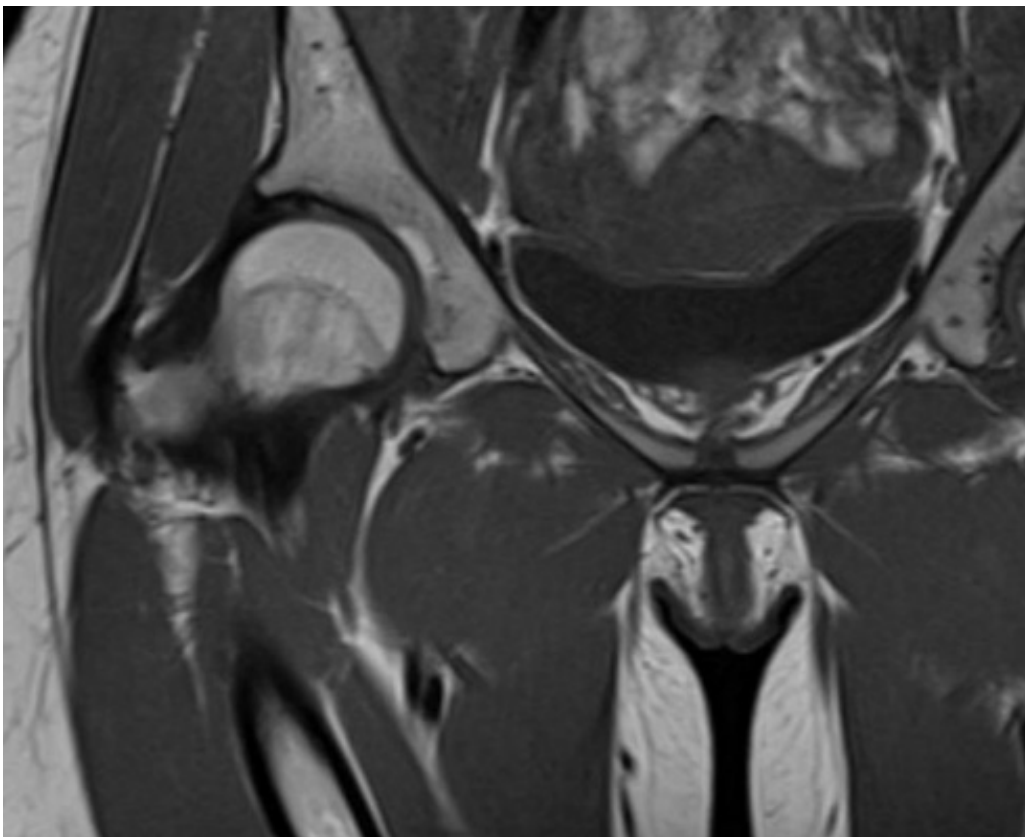
on the first postoperative day with a note not to weight bear the operated leg, and on the third day she was discharged from the hospital. After the hospital treatment, physical rehabilitation was performed for four weeks, so at the control examination after the rehabilitation, the patient did not complain of pain, the movements were neat and painless, and the Harris Hip Score was 51 points. The next control examination of the patient was at the third month after surgery. A native pelvic x-ray showed an increase in bone density in the duct from the surgically made tunnel to the change as well as an increase in bone density in the necrotic zone. The Harris Hip score was 67 points. The patient was advised to move without crutches and to continue strengthening the muscles above the knees.

Six months after surgery, an MRI of the pelvis with both hips was performed. A bone defect was still present at the proximal end of the head of the left femur from the previous decompression with initial chondromalacia of the ipsilateral femoral head and slightly reduced acetabular joint space, but without the presence of an osteochondral lesion. The Harris hip score was 78 points, which indicated a good clinical outcome.

On the control examination 19 months after surgery, the patient was still limping, but had no pain and she returned to everyday activities just like before the condition.

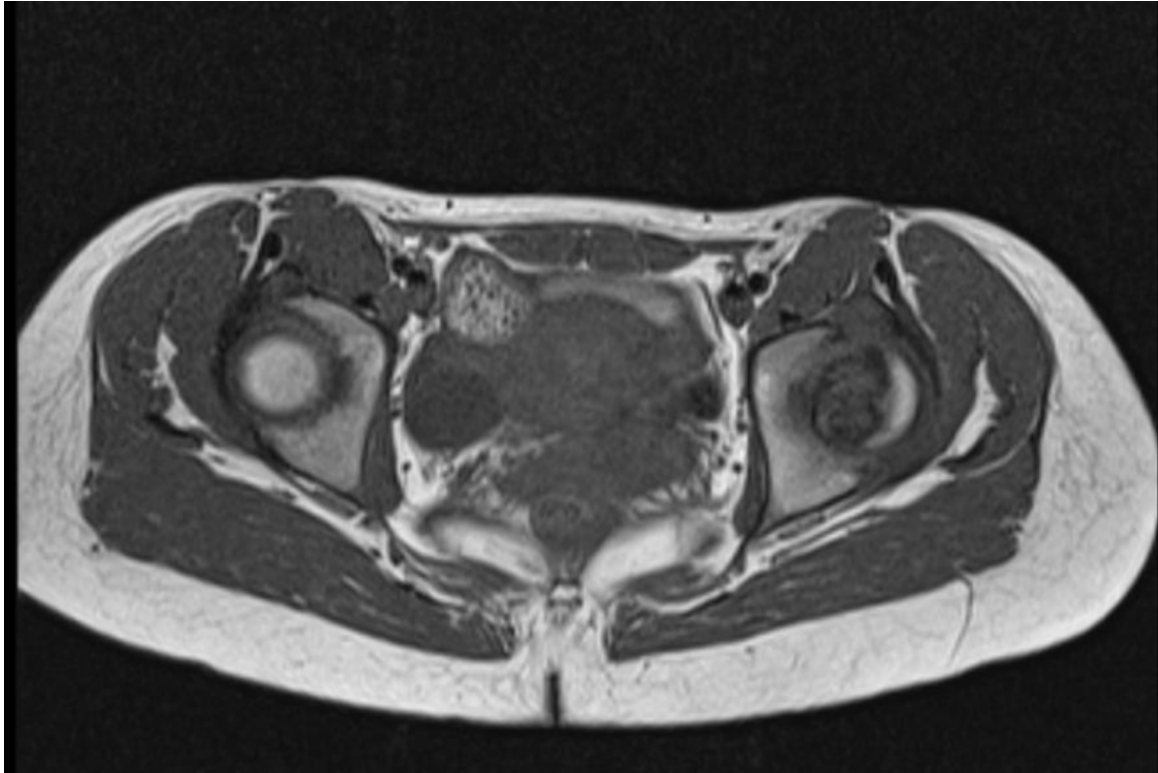


**Fig. 1** Preoperative X ray of the pelvis, showing AVN of the femoral head of the left hip, according to Ficat classification stage3

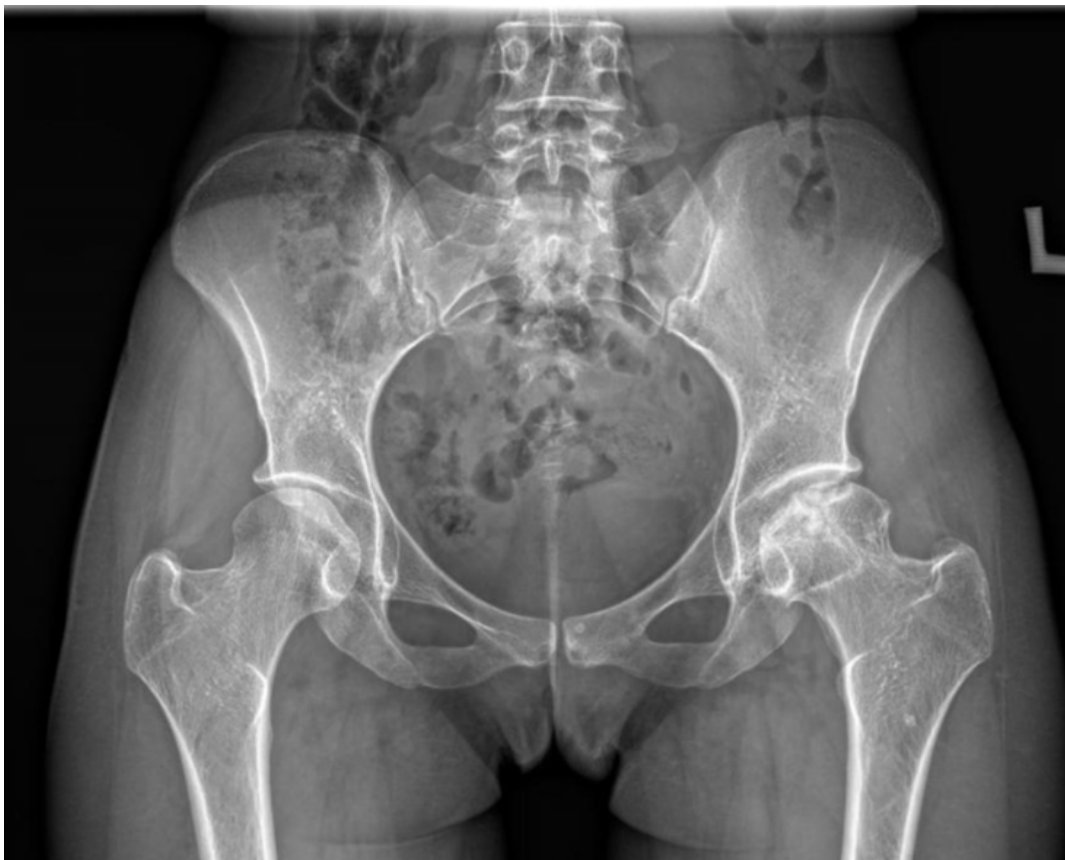

**Fig. 2** Preoperative MRI of the pelvis - coronal view





**Fig. 3** Preoperative MRI of the pelvis - transverse view



**Fig. 4** Control X-ray 19 months after surgery

## Discussion

Corticosteroid-induced avascular necrosis of the femoral head most commonly affects the femoral head, but other skeletal parts are not excluded.<sup>10,11</sup> Majority of patients complain of pain with an insidious onset, which exacerbates with physical activity, and tends to worsen with time. Early diagnosis and treatment are crucial, because treatment modalities in advanced diseases are limited and most of the patients who suffer from this condition are young people and physically active.

The prevalence of corticosteroid-induced avascular necrosis of the femoral head varies between 3-38% and mainly depends on the dosage and route of administration of the drug.<sup>10</sup>

The pathophysiological mechanisms till now have not been fully understood; they include different theories such as fat embolisation, intravascular coagulation, hypertrophy of the fat cell and osteocyte apoptosis, with a common pathway to compromise the vascularization of the bone and the bone marrow, leading to ischemic event and subsequent ischemic necrosis of the bone tissue and finally collapse of the bone.<sup>12</sup> Recently, a new theory for corticosteroid-induced osteocyte apoptosis has been suggested as another pathogenetic mechanism of avascular necrosis of the femoral head, as apoptotic osteocytes were found in a specimen of the femoral head during total hip arthroplasty in a patient who had a medical history of corticosteroid usage.<sup>13,14</sup> These findings are not detected in patients who have avascular necrosis of the femoral head with previous history of trauma or alco-

hol abuse. These osteocytes tend to accumulate in the bone and lead to disruption of the osteocyte-lacunar-canalicular system, as well as in the vascular space and in the end the result is collapse of the femoral head.<sup>15</sup>

As a classical surgical treatment, core decompression itself usually is effective for small necrotic lesions, but the combination of core decompression with application of bone marrow aspirate concentrate is associated with improved radiological signs and clinical outcomes.<sup>16,17</sup>

A large number of transgenic MCS for specific functions have been studied and stem cell technology is rapidly evolving. It is very important to highlight the need of further genetic studies for genetic safety of transgenes and stem cell subpopulations. The strong expression of some specific factors may affect other normal tissues and the effect of small molecule drugs on the differentiation of the stem cells and proliferation has been confirmed. Small molecule drugs seem to be convenient for stem cell pretreatment and may be a research direction for stem cell pretreatment for avascular necrosis of the femoral head in the future.<sup>18</sup>

The major concern regarding treatment with stem cells is their safety. Flushing, fever, mild headache are the complications reported in a few studies.<sup>19-21</sup> It has also been reported in a few studies that transplantation of embryonic stem cells may lead to teratoma formation. Immune rejection and genetic modification can also limit the clinical use of transplanted stem cells for osteonecrosis of the femoral head.<sup>21,22</sup>

The results obtained in this study have shown that after the application

of stem cells in the necrotic zone of the femoral head and after intra-articular application, good functional results have been achieved. Radiographically confirmed good bone regeneration was achieved and the progression of necrosis to a higher degree was prevented.

## Conclusion

The treatment of avascular necrosis of the femoral head through a minimally invasive tunneling and decompression technique and the simultaneous application of autologous mesenchymal stem cells obtained by processing bone marrow taken from the iliac crest gives rapid and biologically effective results as well as good functional results. Despite some controversy regarding the treatment of avascular necrosis of the femoral head with stem cells, the general outcomes of using stem cells appear to be positive in terms of efficacy and safety. The future perspectives are in qualitative and quantitative characterization of cellular therapies.

## References

1. L1. Wang C, Wang Y, Meng HY, Yuan XL, Xu XL, Wang AY, et al. Application of bone marrow mesenchymal stem cells to the treatment of osteonecrosis of the femoral head. *Int J Clin Exp Med* 2015; 8(3):3127-35.
2. Hernigou P, Trousselier M, Roubigneau F, Charlie B, Chevallier N, et al. Stem cell therapy for the treatment of hip osteonecrosis: a 30 year review of progress. *Clin Orthop Surg* 2016; 8(1) 1-8.
3. Matthew T H, Cody C W, John R M and Rafael S. Stem cell treatment for avascular necrosis of the femoral head:current perspectives. *Stem cell Cloning* 2014; 7:65/70.
4. Michael A M, David S H. Non Traumatic Avascular Osteonecrosis of the Femoral Head. *J Bone Joint Surgery AM* 1995; 77A, N-3.
5. George B, VasileosS, Javad P, Panayiotis S. Osteonecrosis of femoral head. *Orthopaedics* 2011; 34 (1): 39-48.
6. Ficat RP. Idiopathic bone necrosis of the femoral head. Early diagnosis and treatment. *J Bone Joint Surg (Br)*. 1985;67(1):3-9.
7. Lars R, Lars E, Stephan R, Johannes C R, Franc J, Heike W, et al. Stem cell-and growth factor-based regenerative therapies of avaskular necrosis of the femoral head. *Stem Cell Res Ther* 2012; 3(1): 7.
8. Hernigou J, Picard L, Alves A, Silvera J, Homma Y, Hernigou P. Understanding bone safety zones during bone marrow aspiration from the iliac crest: the sector rule. *Ind Orthop* 2014; 38(11) 2377-84.
9. Gangii V, Hauser JP, Matos C, De Maertelaer V, Toungous M, Lambertmont M. Treatment of osteonecrosis of the femoral head with implantation of autologous bone marrow cells. A pilot study. *J Bone J Surg Am*. 2004; 86-A (6) 1153-60.
10. Assouline-Dayana Y, Chang C, Greenspan A, Shoenfeld Y, Gershwin ME. Pathogenesis and

- natural history of osteonecrosis. *Semin Arthritis Rheum* 2002; 32(2):94–124.
11. Kelman GJ, Williams GW, Colwell JR CW, Walker RH. Steroid-related osteonecrosis of the knee. Two case reports and a literature review. *Clin Orthop Relat Res* 1990; 257:171–6.
  13. Kabata T, Kubo T, Matsumoto T. Apoptotic cell death in steroid induced osteonecrosis: an experimental study in rabbits. *J Rheumatol* 2000; 27(9 ):2166–71.
  14. Calder JD, Buttery L, Revell PA, Pearse M, Polak JM. Apoptosis--a significant cause of bone cell death in osteonecrosis of the femoral head. *J Bone Joint Surg Br.* 2004;86(8 ):1209–13.
  15. Weinstein RS, Nicholas RW, Manolagas SC. Apoptosis of osteocytes in glucocorticoid induced osteonecrosis of the hip. *Endocrinology* 2000;85(8 ):2907
  16. El-Jawhari JJ, Ganguly P, Jones E, Giannoudis PV. Bone marrow multipotent mesenchymal stromal cells as autologous therapy for osteonecrosis: Effects of age and underlying causes. *Bioengineering* 2021; 8(5):69.
  17. Tabatabaee RM, Saberi S, Parvizi J, Mortazavi SM, Farzan M. Combining concentrated autologous bone marrow stem cells injection with core decompression improves outcome for patients with early-stage osteonecrosis of the femoral head: A comparative study. *J Arthroplast* 2015, 30 (Suppl. 9), 11–15.
  18. Wang Y, Ma X, Chai W, Tian J. Multiscale stem cell technologies for osteonecrosis of the femoral head. *Stem Cells International* 2019; 2019
  19. Aoyama T, Goto K, Kakinoki R, Ikeguchi R, Ueda M, Kasai Y, et al. An exploratory clinical trial for idiopathic osteonecrosis of femoral head by cultured autologous multipotent mesenchymal stromal cells augmented with vascularized bone grafts. *Tissue Eng B Rev* 2014;20(4):233–242.
  20. Pilge H, Bittersohl B, Schnependahl J, Hesper T, Zilkens C, Ruppert M, et al. Bone marrow aspirate concentrate in combination with intravenous iloprost increases bone healing in patients with avascular necrosis of the femoral head: A matched pair analysis. *Orthop Rev* 2016;8(4):6902.
  21. Li R, Lin Q X, Liang X Z, Liu G B, Tang H, Wang Y, et al. Stem cell therapy for treating osteonecrosis of the femoral head: From clinical applications to related basic research. *Stem cell research & therapy* 2018; 9(1): 291.
  22. Brederlau A, Correia AS, Anisimov SV, Elmi M, Paul G, Roybon L, et al. Transplantation of human embryonic stem cell-derived cells to a rat model of Parkinson's disease: effect of in vitro differentiation on graft survival and teratoma formation. *Stem Cells* 2006; 24(6):1433–1440.